

## CASE REPORT

# Surgical removal of a dermoid cyst from the bony part of the nasolacrimal duct in a Scottish highland cattle heifer

Andrea Steinmetz,\* Lena Locher,† Uta Delling,‡ Jean-Claude Ionita,‡ Eberhard Ludewig,\* Gerhard Oechtering\* and Thomas Wittek†

\*Department of Small Animal Medicine, University of Leipzig, An den Tierkliniken 23, D-04103 Leipzig, Germany; †Clinic for Large Animal Internal Medicine, University of Leipzig, An den Tierkliniken 11; D-04103 Leipzig, Germany; ‡Large Animal Clinic for Surgery, University of Leipzig, An den Tierkliniken 21, D-04103 Leipzig, Germany

Address communications to:

A. Steinmetz

Tel.: +1149 341 9738700

Fax: +01149 3419738799

e-mail: steinmetz@kleintierklinik.uni-leipzig.de

## Abstract

The ophthalmologic, radiologic and surgical findings of a 2-year-old Scottish Highland Cattle heifer with a dermoid cyst within the bony part of the nasolacrimal duct and the successful treatment are presented.

**Key Words:** cattle, dacryocystorhinography, dermoid cyst, nasolacrimal duct, purulent ocular discharge, surgical treatment

## INTRODUCTION

Dermoid cysts are developmental abnormalities of the skin which are often found in the midline of the body. The contents of the cysts often include hairs and glandular secretions.<sup>1</sup> Dermoid cysts are most frequently seen in Rhodesian Ridgeback dogs, but have also been reported in cattle.<sup>1–5</sup> Facial dermoid cysts were described in human patients, dogs and cattle<sup>2–9</sup> and may extend through the nasal bones and communicate with the nasolacrimal duct.<sup>5,9</sup>

This report describes a dermoid cyst that entered the bony part of the nasolacrimal duct and caused purulent ocular discharge resistant to medical therapy in a 2-year-old Scottish Highland Cattle heifer and the successful surgical treatment of this condition.

## CASE REPORT

### History and initial clinical findings

A 2-year-old female Scottish Highland Cattle heifer was presented with the history of purulent discharge from the OD and the right nostril (Fig. 1). The animal was kept on pasture in a herd. Symptoms had been present for about 6 months. A bacteriologic examination had revealed *Arcanobacterium pyogenes* and *Staphylococcus saprophyticus*. The application of eye drops QID (Ofloxacin, Floxal<sup>®</sup>, Dr Mann Pharma, Berlin, Germany) and systemic amoxicillin treatment (11 mg/kg BID, Amoxisel<sup>®</sup>, Selectavet, Weyarn-Holzolling, Germany) were unsuccessful in reducing the discharge.

Initial physical examination revealed massive mucopurulent discharge from the OD, especially from the inferior

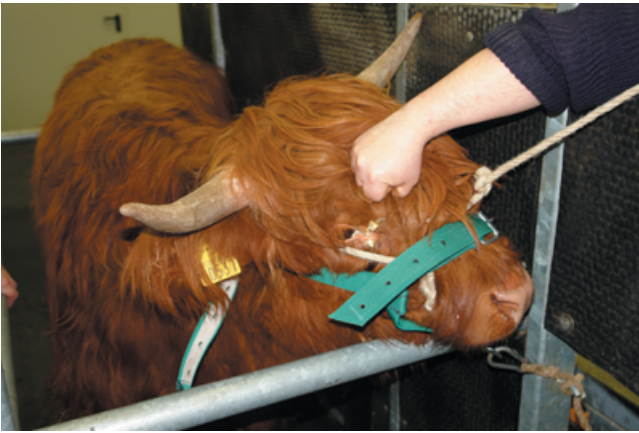lacrimal punctum (Fig. 2). There was a small subcutaneous swelling about 9 cm distal from the medial canthus. Apart from these findings, the animal did not show any additional pathological symptoms. The OS was completely normal.

### Results of additional diagnostic procedures

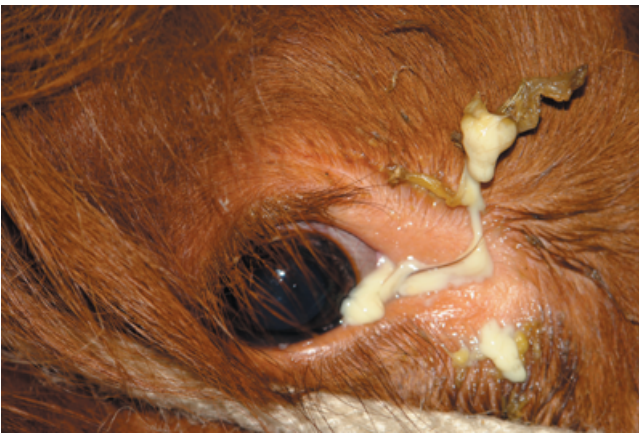Gross examination of cleaned medial canthus revealed several long brown hairs growing out of the inferior punctum and confirmed by biomicroscopy (SL 14, Kowa Company Ltd, Tokyo, Japan) (Fig. 3). The eyelids, the cornea and the anterior chamber were normal. The IOP (TonoPen-XL, Mentor O&O, Norwell, MA; topical anesthetic Oxybuprocainhydrochloride, Novesine<sup>®</sup>, OmniVision, Puchheim, Germany) was 15 mmHg.

Bacteriological examination revealed *Arcanobacterium pyogenes* and *Staphylococcus saprophyticus*, which was identical to the culture results that have been described in the history. Lavage of the nasolacrimal duct via the superior punctum was possible, but impossible via the inferior punctum. This finding was confirmed by placing a catheter in the nasal opening of the nasolacrimal duct and performing a retrograde lavage.

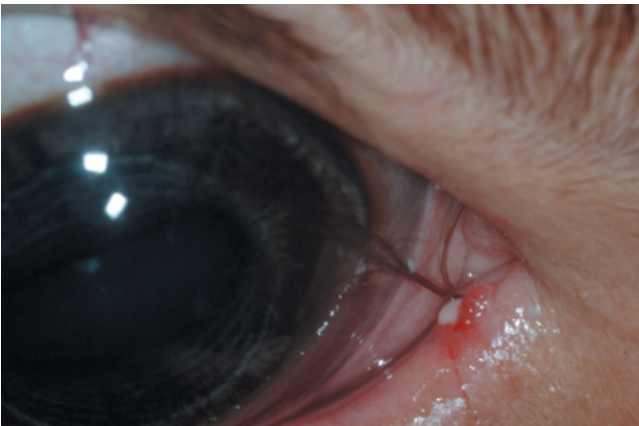Afterwards a bilateral dacryocystorhinography, using the iodinated contrast medium Iopamidol (Solutrast 250, Altana Pharma GmbH, Konstanz, Germany) diluted with 50% methyl cellulose (Methocel<sup>®</sup>, OmniVision, Puchheim, Germany), was performed. This revealed that the contrast column ended in a cystic structure about 8 cm distal to the medial orbital margin at the level of the swelling (Fig. 4). A dermoid cyst within the bony part of the nasolacrimal duct and secondary infection were suspected. Results indicated the need for surgical intervention to remove the cyst.



**Figure 1.** Purulent discharge on the OD and the right nostril.



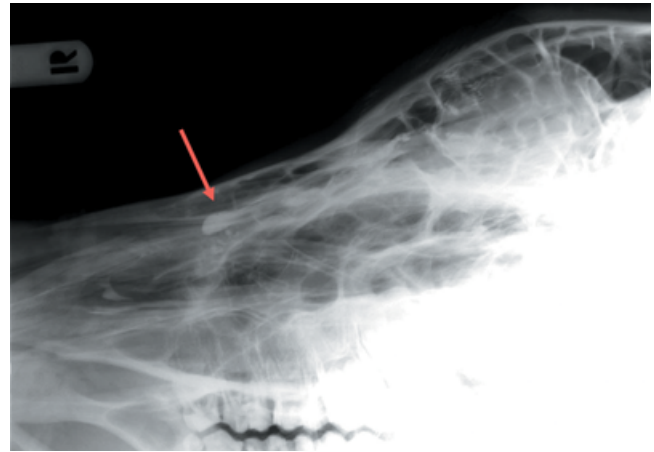
**Figure 2.** Massive purulent discharge on the OD.



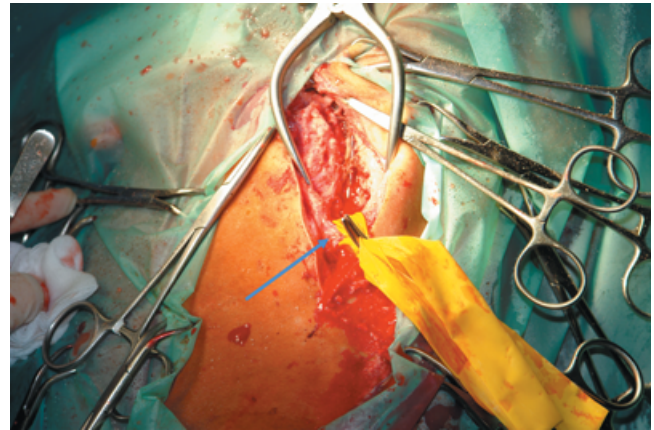
**Figure 3.** A couple of long brown hairs grew out of the inferior punctum.

### *Surgery*

Preoperative sedation of the heifer was achieved using an intramuscular administration of xylazine (0.1 mg/kg of body weight; Xylazin 2%<sup>®</sup>, CP-Pharma GmbH, Burgdorf, Germany) followed by a combination of intravenously administered xylazine (0.045 mg/kg of body weight; Xylazin 2%<sup>®</sup>, CP-



**Figure 4.** Tubular contrastmedium filled structure (red arrow), no further rostral drainage could be visualized.



**Figure 5.** Care was taken to avoid damage to the infra-orbital nerve, artery and vein (inside the penrose drain, blue arrow).

Pharma GmbH) and butorphanol (0.01 mg/kg of body weight; Torbugesic<sup>®</sup>, Fort Dodge, Würselen, Germany). After placement of a 14 G catheter in the right jugular vein, the patient also received flunixin-meglumin (2.2 mg/kg of body weight; Flunidol RP<sup>®</sup>, CP-Pharma GmbH) for intravenous peri-operative analgesia. Anesthesia was intravenously induced using ketamine hydrochloride (2.5 mg/kg; Ursotamin<sup>®</sup>, Serum-Werk-Bernburg AG, Bernburg, Germany) followed by sodium thiopental (0.16 mg/kg; Trapanal<sup>®</sup>, Altana Pharma, Konstanz, Germany), and maintained by inhalation anesthesia with isoflurane (Isofluran CP<sup>®</sup>, CP-Pharma GmbH) in 100% oxygen after endotracheal intubation.

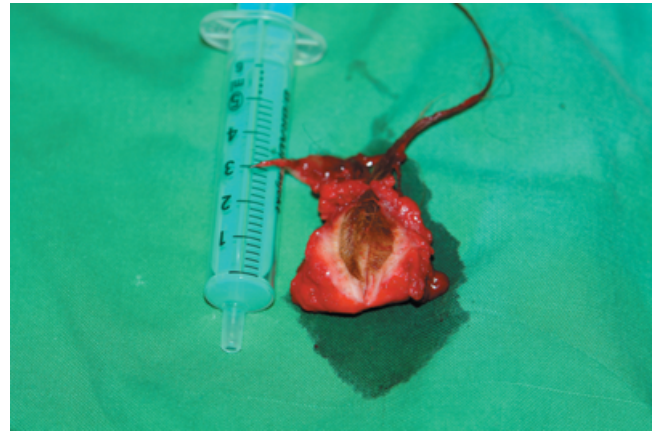A probe was placed through the inferior lacrimal punctum into the lacrimal duct. The lacrimal duct was opened from the small inferior part, starting a couple centimeters below the inferior punctum, thus leaving the inferior punctum intact, extending the incision in a slightly curved manner towards the right nostril. The final soft tissue incision was about 20 cm long and extended to the level of the periosteum of the lacrimal and the maxillary bone. At the beginning of the



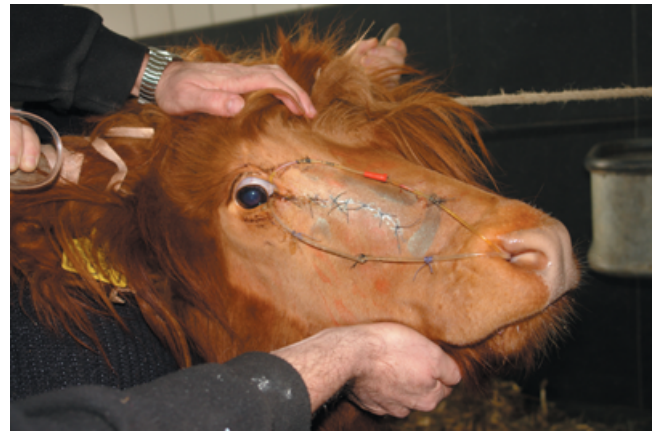**Figure 6.** The cyst divided the osseous line between lacrimal and maxillary bone and entered the nasolacrimal duct. It filled the aboral part of the lacrimal duct completely with hairs from about 8–15 cm length.

bony part of the lacrimal duct, a bone drill was used to open the canal until the cyst was entered. Care was taken to avoid damage to the infra-orbital nerve, artery and vein (Fig. 5). Surgery revealed that the cyst divided the osseous line between lacrimal and maxillary bone and entered the nasolacrimal duct. It filled the aboral part of the lacrimal duct completely with hairs from about 8–15 cm length (Fig. 6). The cyst wall and the hair were completely removed (Fig. 7) and the remaining oral part of the duct was irrigated. Before closing the wound two catheters were passed through the superior and the inferior lacrimal puncta respectively towards the nasal opening. Catheters were sutured to each other forming two circles and to the skin to maintain nasolacrimal duct patency and remained in place for 2 months (Fig. 8).

Gentamicin eye drops (Gentamicin-POS<sup>®</sup>, Ursapharm, Saarbrücken, Germany) were administered topically five times a day for 2 weeks. Systemic antibiotic (marbofloxacin 2 mg/kg BW, Marbocyl<sup>®</sup>, Vetoquinol, Ravensburg, Germany) and anti-inflammatory (flunixin-meglumine 2.2 mg/kg BW, Finadyne RPS, Essex Tierarznei, Munich, Germany) treatment was administered over 7 days after surgery.



**Figure 7.** The dermoid cyst.



**Figure 8.** Catheters were sutured to each other forming two circles and to the skin to maintain nasolacrimal duct patency.

#### *Outcome*

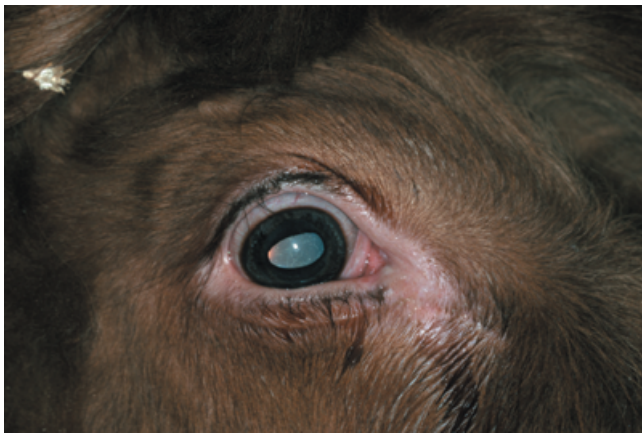Four weeks after surgery a subcutaneous abscess had formed at a part of the incision site. After incising the abscess and leaving it open to restore by second intention it healed without any further complication. Antibiotic and antiphlogistic treatment as described above was administered again over 7 days.

The follow up period lasted 3 months. During the final clinical examination the heifer showed mild serous ocular discharge without any signs of discomfort (Fig. 9). Irrigating the lacrimal duct via the inferior lacrimal punctum was possible but required higher pressure in comparison the superior lacrimal punctum. No re-growth of the hairs or signs of inflammation could be detected.

#### **DISCUSSION**

Massive unilateral purulent ocular discharge was the predominant clinical symptom in this case. Causes of purulent ocular discharge in cattle are infectious and parasitic conjunctivitis and congenital abnormalities of the outer part of the eye and the nasolacrimal duct.<sup>10</sup> Because of the long





**Figure 9.** Final examination: the heifer showed mild serous discharge without any signs of discomfort.

hairs growing out of the inferior lacrimal punctum an anomalous nasolacrimal duct was suspected in this case. Congenital anomalies of the nasolacrimal system are rare in cattle.<sup>5,11–13</sup> Supernumerary openings of the nasolacrimal drainage apparatus and dysplastic lacrimal puncta have been described in calves.<sup>11–13</sup> Only one report described a dermoid cyst which affected the nasolacrimal duct in a bull.<sup>5</sup> Other facial dermoid cysts in cattle have been reported in the ocular and periocular regions.<sup>2,4</sup>

Like previously described,<sup>5</sup> dacryocystorhinography was useful to diagnose a cystic obstruction of the nasolacrimal duct in this study.

Surgery revealed that the cyst invaded the bony skull in the osseous line between lacrimal and maxillary bone and entered the lacrimal duct. This condition has been already described in Humans and in one case in cattle.<sup>5,9</sup>

Different to literature<sup>5</sup> in this case the outer component of the bony part of the lacrimal duct was excised to remove the hairs and cyst wall completely and to maintain the original duct. A conjunctivorhinostomy was not performed. At the final clinical examination a post surgical constriction of the lower lacrimal duct was seen but the nasolacrimal duct itself was patent.

To the best of our knowledge this is the first report about surgical removal of a dermoid cyst from the bony part of the nasolacrimal duct with preservation of the original nasolacrimal duct in cattle.

#### ACKNOWLEDGMENT

We gratefully acknowledge DVM Laura Beasley for perusal and amendment.

#### REFERENCES

1. Scarf DH. Nodular lesions. In: *Manual of Small Animal Dermatology*, 1st edn. (eds Locke PH, Harvey RG, Mason IS). Gloucestershire, BSAVA, 1993; 65–73.
2. Adams SB, Horstman L, Hoerr FJ. Periocular dermoid cyst in a calf. *Journal of the American Veterinary Medical Association* 1983; **182**: 1255–1256.
3. Baird AN, Wolfe DF, Groth AH. Dermoid cyst in a bull. *Journal of the American Veterinary Medical Association* 1993; **202**: 298.
4. Gelatt KN. Corneo-conjunctival dermoid cyst in a calf. *Veterinary Medicine Small Animal Clinical* 1972; **67**: 1217.
5. Wilkie DA, Rings DM. Repair of anomalous nasolacrimal duct in a bull by use of conjunctivorhinostomy. *Journal of the American Veterinary Medical Association* 1990; **196**: 1647–1650.
6. Burrow RD. A nasal dermoid sinus in an English bull terrier. *Journal of Small Animal Practice* 2004; **45**: 572–574.
7. Cambiaghi S, Micheli S, Talamonti G *et al.* Nasal dermoid sinus cyst. *Pediatric Dermatology* 2007; **24**: 646–650.
8. Khanna G, Sato Y, Smith RJ *et al.* Causes of facial swelling in pediatric patients: correlation of clinical and radiologic findings. *Radiographics* 2006; **26**: 157–171.
9. Sreetharan V, Kangesu L, Sommerlad BC. Atypical congenital dermoids of the face: a 25-year experience. *Journal of Plastic, Reconstructive and Aesthetic Surgery* 2007; **60**: 1025–1029.
10. Townsend WM. Food an fiber-producing animal ophthalmology. In: *Veterinary Ophthalmology*, 4th edn. (ed. Gelatt KN). Blackwell Publishing, Iowa, 2008; 1275–1335.
11. Heider L, Wyman M, Burt J *et al.* Nasolacrimal duct anomaly in calves. *Journal of the American Veterinary Medical Association* 1975; **167**: 145–147.
12. van der Woerd A, Wilkie DA, Gilger BC. Congenital epiphora in a calf associated with dysplastic lacrimal puncta. *Agricultural Practice* 1996; **17**: 7–11.
13. McLaughlin SA, Brightman AH, Nelson DR. Nasolacrimal duct anomaly in Holstein calf. *Agricultural Practice* 1985; **6**: 30–31.